Chapter 5

Airway/Breathing

Introduction

Skillful, rapid, assessment and management of airway and ventilation are critical to preventing morbidity and mortality. Airway compromise can occur rapidly or slowly and may recur. Frequent reassessment is necessary. Preventable causes of death from airway problems in trauma include the following:

- Failure to recognize the need for an airway.
- Inability to establish an airway.
- Failure to recognize the incorrect placement of an airway.
- Displacement of a previously established airway.
- Failure to recognize the need for ventilation.
- Aspiration of the gastric contents.

Initial airway management at any level, but especially outside of medical treatment facilities (MTFs).

Immediate goal: Move tongue, pharyngeal soft tissues, and secretions out of airway. **Until a formal airway is established, place patients in the lateral or prone position (rescue position).**

- Chin-lift and head tilt: Place fingers under the tip of the mandible to lift the chin outward from face.
- Two-Handed Jaw Thrust: Place both hands behind the angles of the mandible and displace forward. This method can be used on the patient with cervical injury.
- Oropharyngeal airway:
  - Insert oral airway upright if a tongue depressor is used (preferred method).
  - Keep the airway inverted past the tongue then rotate 180°.
  - Too small an airway will not alleviate the obstruction. Too long an airway may fold the epiglottis caudally, worsening the obstruction.
  - Estimate airway size by distance from corner of mouth to ear lobe.
  - Oral airways are not used in conscious patients.

- Nasopharyngeal airway.
  - o Pass lubricated nasal airway gently through one nostril.
  - o Not used in suspected facial or basal skull injuries.
  - o Is tolerated by conscious patients.
- Field expedient.
  - o Pull tongue forward and safety pin or suture it to corner of mouth.
- Cricothyrotomy.

Ventilation

- Ventilate patient with bag valve mask (BVM).
  - o **Bring the face into the mask rather than pushing the mask onto the face**.
  - o The chin-lift and head tilt are also employed during mask ventilation unless they are contraindicated due to cervical spine precautions.

Assess air movement during mask ventilation by observing rise and fall of the chest, auscultation, absence of a mask leak, compliant feel of self-inflating bag, and stable oxygen saturation.

  - o If air movement is not achieved, use **two-person mask ventilation** (Fig. 5-1).

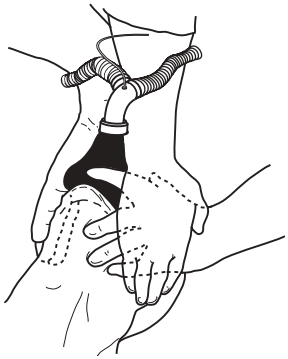

Fig. 5-1. Two-person mask ventilation.

- ♦ One person lifts the jaw aggressively at the angles of the mandible; the other holds the mask and ventilates. Alternatively, one person may lift and hold the mandible with both hands, while at the same time holding down the mask on both sides. The other person ventilates the patient.
- ♦ If air movement is still not present, obtain a definitive airway.

- o Unsuccessful and aggressive attempts at ventilation may result in inflation of the stomach, placing the patient at increased risk for vomiting and aspiration.

Positive pressure ventilation can convert a simple pneumothorax into a tension pneumothorax. Perform frequent assessment and have equipment available for needle chest decompression.

Orotracheal Intubation

Rapid Sequence Intubation (RSI)—7 steps.

1. Preoxygenate with 100% oxygen by mask.
2. Consider fentanyl—titrate to maintain adequate blood pressure and effect (2.0–2.5 μg/kg).
3. Cricoid Pressure—Sellick maneuver until endotracheal tube (ETT) placement is confirmed and balloon is inflated.
4. Induction Agent: etomidate 0.1–0.4 mg/kg IV push.
5. Muscle Relaxant: succinylcholine 1.0–1.5 mg/kg IV push.
6. Laryngoscopy and orotracheal intubation.
7. Verify tube placement.

- Direct laryngoscopy technique.
  - o Ensure optimal "sniffing" position is achieved unless contraindicated by cervical spine injury.
  - o Open the mouth by scissoring the right thumb and middle finger.
  - o Hold the laryngoscope in the left hand and insert the blade along the right side of the mouth, slightly displacing the tongue to the left.
    - ♦ **Macintosh** (curved) blade: Advance the tip of the blade

into the space between the base of the tongue and the epiglottis (valecula). Apply force at a 30°–45° angle, lifting the entire laryngoscope/blade, without rocking it backward (Fig. 5-2).

- **Miller** (straight) blade: Advance the tip of the blade into the posterior oropharynx, picking up the epiglottis and tongue base anteriorly and laterally, and apply a force vector like that of the Macintosh blade. Avoid rocking the laryngoscope backward (Fig. 5-3).

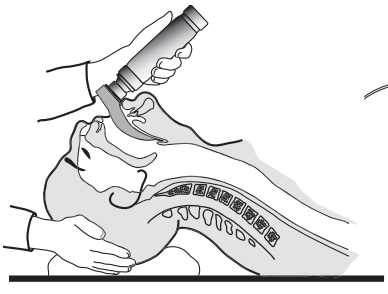

Fig. 5-2. Use of curved blade laryngoscope.

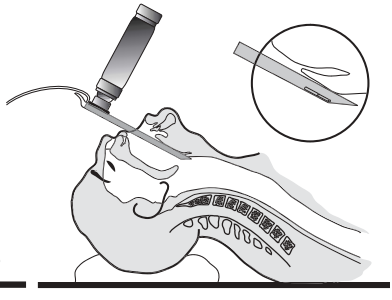

Fig. 5-3. Use of straight blade laryngoscope.

- Visualize the vocal cords.
- Consider the "BURP" maneuver when the laryngoscopic view is poor (Fig. 5-4).
  - "Backward-Upward-Rightward-Pressure" of the larynx, also referred to as external laryngeal manipulation.
  - Place the fingers of an assistant onto the larynx with your right hand and manipulate the glottic opening into the field of view.
  - Assistant then holds the position for intubation.

Eschmann stylet or Gum Elastic Bougie (GEB) (Fig. 5-5).

- Blindly guide the tip of the stylet beneath the epiglottis, then anteriorly through the vocal cords.
- Advance the bougie deeply. Placement into the trachea results in the sensation of tracheal ring "clicks", and turning of the stylet as it passes airway bifurcations.

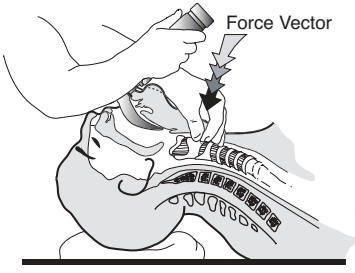

Fig. 5-4. BURP maneuver.

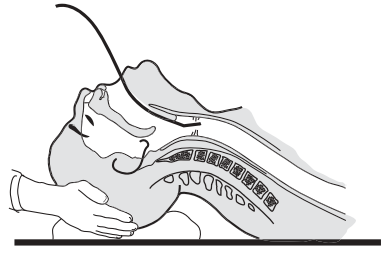

Fig. 5-5. Eschmann stylet in place.

- ♦ The patient may cough as the stylet passes through the airway.
- ♦ When passed beyond the trachea, the stylet will stop at a terminal bronchus. If placed into the esophagus, it will pass indefinitely into the stomach without any tactile feedback.
- ♦ The ETT is guided over the stylet into the airway, and tracheal intubation is confirmed.

- o Advance the ETT between the vocal cords, withdraw stylet, and advance the ETT to 20–21 cm at the teeth for adult females, 22–23 cm for adult males. Deeper placement may result in right mainstem intubation.
- o Confirm placement of the ETT in the trachea.
- o Auscultate over the axilla to ensure breath sounds are equal.

Avoid making more than 3 attempts at direct laryngoscopy. Excessive attempts may result in airway trauma and swelling, potentially turning a "cannot intubate" urgency into a "cannot intubate-cannot ventilate"emergency.

Difficult Airway

After three unsuccessful attempts at direct laryngoscopy, abandon the technique and try alternatives.

- Alternative intubation techniques.
  - o Tactile intubation.
    - ♦ Requires no instruments.

    - ♦ No light use—good in light control situations.
    - ♦ Slide hand closest to patient over tongue to hold it down.
    - ♦ Lift epiglottis with first two fingers.
    - ♦ Slide ETT along the "v" between the two fingers into the airway.
  - o Lighted stylet or "light wand" intubation.
    - ♦ Flexible wand, lighted at the tip, is placed through the ETT.
    - ♦ Wand is advanced by tactile guidance into the trachea.
    - ♦ Position in trachea is verified by transillumination.
    - ♦ The ETT is advanced over the wand.
  - o Flexible fiberoptic oral or nasal intubation.
  - o Retrograde wire intubation.
  - o Rigid fiberoptic intubation (Bullard laryngoscope).
  - o Alternative Airways.
    - ♦ May NOT be definitive airways.
    - ♦ Allow for oxygenation and ventilation when standard airways cannot be placed.
    - ♦ "Fastrach" model laryngeal mask airway (LMA).
    - ♦ Esophageal-tracheal combitube (ETC).
- Perform a surgical airway.
- Wake the patient up and attempt an awake technique if possible.

Surgical Cricothyrotomy

- Identify cricothyroid membrane (between cricoid ring and thyroid cartilage [Fig. 5-6a]).
- Prep skin widely.
- Grasp and hold trachea until airway is completely in place.
- Make a **vertical SKIN** incision down to the cricothyroid membrane (a No. 10 or 11 blade).
- Bluntly dissect the tissues to expose the membrane.
- Make a **horizontal MEMBRANE** incision (Fig. 5-6b).
- Open the membrane with forceps or the scalpel handle.
- Insert a small, cuffed ETT, 6.0–7.0 inner diameter (ID), to just above the balloon (Fig. 5-6c).
- Confirm tracheal intubation.

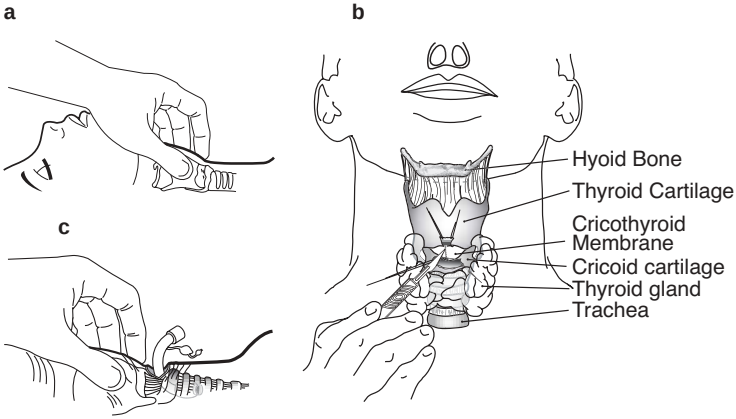

Fig. 5-6 a,b,c. Steps of surgical cricothyrotomy.

- Suture the ETT in place, and secure it with ties that pass around the neck.

Laryngeal Mask Airway

Do NOT use in penetrating upper airway trauma or central airway obstruction (foreign body).

- Insert blindly without a laryngoscope. LMA rests over the laryngeal inlet (Fig. 5-7).

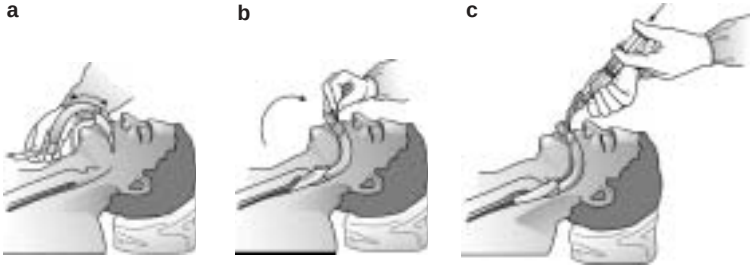

Fig. 5-7 a,b,c. Fastrach laryngeal mask airway placement. Illustration courtesy of LMA North America, Inc.

- May be used alone or as a conduit to advance an ETT.
- Compared to an ETT, the LMA supports less airway pressures, and offers less aspiration protection.
- Check LMA cuff, then deflate it until the down side (inner) surface is smooth and flat; lubricate the pharyngeal (upper) side of LMA.
- The sniffing position works best, but LMA may be inserted in different patient positions.
  - Insert LMA (3–4 for women, 4–5 for men) with upper (pharyngeal) side **gliding along the hard palate, down and around into the posterior pharynx**—this allows proper direction and reduces the chance of cuff folding.
  - Do **NOT** push the LMA directly back into the mouth—this folds the cuff and prohibits proper placement.
  - Inflate cuff with 20–30 cc of air via syringe—slight upward movement of LMA tubing is seen.
  - Secure the LMA.

Blind nasal-tracheal intubation

Contraindications: Coagulopathy, midface trauma, basilar skull fracture, and suspected elevated intracranial pressure.

- Nasal-trachael intubation is better tolerated than orotracheal techniques and requires less sedation and no paralysis.
- Prepare the nasopharynx and larynx (as conditions allow).
  - Spray vasoconstrictor into the nostril that appears largest and most patent.
  - Insert a nasal trumpet soaked in lidocaine gel and leave in place for a brief period.
  - Apply Cetacaine spray to oropharynx.
  - Administer a transtracheal injection of 4 cc lidocaine via cricothyroid membrane.
- Insert an ETT (~ 7.0 ID for adults) slowly into the nostril, perpendicular to the face.
- Advance the ETT slowly past the nasal turbinates and around the curve of the posterior nasopharynx.
- **Do not use excessive force!**

- The ETT is advanced as breath sounds of increasing volume are heard at the distal end of the tube.
- The ETT is advanced beyond the vocal cords into the trachea. If the tube fails to advance into the trachea, several maneuvers can be employed.
  - Tilt the head.
  - Apply external, downward pressure to the larynx.
  - Inflate the ETT balloon to help center the tube, then deflate and advance it once it is engaged in the glottic opening.